

Patient Research Terms and Conditions

The terms and conditions set out below govern your use of the content made available through this web-site (the "Site"), including the article or articles that you have selected in connection with your personal medical research (the "Content") for delivery to the e-mail address you will be asked to provide in connection with this service (collectively, the "Service"). In order to provide this Service you understand and agree to provide the personal information you will be asked to provide after you accept these terms and conditions, although our use of such information will be limited to this purpose and otherwise governed by our privacy policy (see Privacy Policy). The Content, the Site and the Service are provided by Elsevier Inc. and its affiliates and licensors (collectively "Elsevier"). For further information about Elsevier or to contact us, see Contact Us.

Permitted Uses

You may access in a given twenty-four hour period a reasonable number of Content items, and you may download and print such Content after it has been delivered to your e-mail address. Such access and use is for your own personal use, although you may also share and discuss such Content with family members and medical professionals involved in your medical care or the care of a family member. You can make further copies for such family members and medical professionals.

Prohibited Uses

Personal use does not include the use by researchers, instructors or students for research purposes or educational use.

You may not copy, display, distribute, modify, publish, reproduce, store, transmit, create derivative works from, or sell or license all or any part of the Content, or any other information obtained from or accessed through this Service in any medium to anyone. You may not modify in any way the text of the Content.

You may not use any robots, spiders, crawlers or other automated downloading programs or devices to: (i) continuously and automatically search or index the Site or the Content, unless authorized by us; (ii) harvest personal information from this web site for purposes of sending unsolicited or unauthorized material; or (iii) cause disruption to the working of the Service or this Site.

You may not use the Service or this Site to publish or distribute any advertising, promotional material, or solicitation to other users to use any goods or services.

Copyright Notice

All Content provided through this Service, and the Site layout, design, images, programs, text and other information displayed, are the property of Elsevier and is protected by copyright and other intellectual property laws.

See the full set of Terms & Conditions on the Patient Research website.



Corticosteroid Addiction and Withdrawal in the Atopic: The Red Burning Skin Syndrome

MARVIN J. RAPAPORT, MD
MARK LEBWOHL, MD

We recently reported 100 patients with a chronic eyelid dermatitis that did not resolve until all topical and systemic corticosteroids had been discontinued.¹ All of these patients had been treated with long-term topical corticosteroids, usually with escalating dosage and frequency of application. In the majority of patients, the initial symptom of pruritus commonly evolved into a characteristic, severe burning sensation. In many cases, systemic corticosteroids had also been administered to relieve the severe erythema and burning, but this only exacerbated the condition. In our opinion the continuing dermatitis resulted from "steroid addiction." Unfortunately, the time required for corticosteroid withdrawal mirrored the time over which they had originally been applied, and was often protracted.

Examination of eyelid skin usually revealed atrophy and telangiectasia. Patch testing, including four different corticosteroid allergens, demonstrated only irritant reactions but no relevant allergens. The corticosteroid antigens included budesonide, hydroxy-17-butyrate, clobetasol-17-propionate, and tixocortol. Of 100 patients, 87 were cured, but only after total cessation of corticosteroid usage. Withdrawal symptoms, manifested by angry erythema and burning, were long-lasting and severe. Although neither Cushing's syndrome or adrenal insufficiency occurred, marked localized and systemic edema developed in some patients. Thirteen patients, unable to tolerate the severe flares on corticosteroid withdrawal, continued using these preparations and continued to exhibit skin rashes. They eventually sought medical care with other practitioners and were lost to follow-up.

This paper expands our previous observations to include patients with similar syndromes localized in other body areas. These include "red face syndrome," post-laser-peel syndrome, status cosmeticus, "red scro-

tum syndrome," vulvodinia, anal atrophoderma, chronic actinic dermatitis, and "chronic eczema" in other body areas (Table 1). These conditions similarly resolved upon discontinuation of corticosteroids, suggesting that a significant proportion of these syndromes are attributable to chronic corticosteroid usage and "corticosteroid addiction." The medical literature pertaining to these syndromes usually has implicated sun exposure, occult allergens, or psychosomatic reactions as the cause of ongoing skin eruptions.²⁻⁴ We consider "corticosteroid addiction" of the skin to be the pertinent etiologic factor in the majority of these patients.

Syndromes

Red Face Syndrome

Two hundred and one patients with chronic red face syndrome were seen, 80% of whom began with eyelid dermatitis. The others had cheilitis, perioral rashes, or nonspecific eczematous eruptions on the forehead or cheeks. Most of these patients (90%) were diagnosed with atopic dermatitis, while 10% had seborrheic dermatitis or "dry skin." The "headlight sign," resulting from sparing of the nose and upper lip on an otherwise red face, was common. Erythema often ended at mid-cheek, and normal unaffected skin was evident from the midcheek to the ears.⁵

Case 1 (32-year-old Woman—Atopic)

This patient developed a mild rash on the eyelids 9 months before her first consultation with us (Fig 1A). She previously had been treated with medium-strength topical corticosteroids. Over a 9-month period, the patient consulted 8 physicians (3 allergists, 2 dermatologists, 2 ophthalmologists and 1 otolaryngologist), many of whom prescribed increasingly potent topical corticosteroids and intramuscular (IM) triamcinolone injections. Patch tests showed only a weak (1+) positive reaction to cobalt.

When corticosteroids were stopped, an erythematous, edematous flare began around the eyes that then spread to the entire face. A few weeks later, marked redness and severe burning developed on the neck and upper chest (Fig 1B). She was treated symptomatically

From the Department of Dermatology, UCLA School of Medicine, Los Angeles, California; and the Department of Dermatology, Mt. Sinai Medical Center, New York, New York.

Address correspondence to Marvin J. Rapaport, MD, 436 N. Bedford Drive, #306, Beverly Hills, CA 90210.

E-mail address: rapnadad@aol.com

Table 1. Duration of withdrawal symptoms

Syndrome	Symptoms on steroid withdrawal	Withdrawal period
Red face syndrome	Local spread, erythema, burning, edema	1–30months
Post-laser peel erythema	Severe burning and erythema	2–12months
Status cosmeticus	Burning, rare acneiform papules	4–12months
Red scrotum syndrome	Burning, edema, vesiculation, erythema	4–18months
Vulvodinia	Burning, slight local spread	12–18months
Anal atrophoderma	Burning, vesiculation, erythema	6–18months
Chronic actinic dermatitis	Severe burning, edema, local and distant spread	12–24months
“Chronic eczema”	Vesiculation, burning, edema, local and distant spread	3–12months

with Burow's compresses, oatmeal lotion, and baths. With the patient off all corticosteroids, 6 months of repeated flares ensued, followed by complete clearing for 4 months. Then, with no identifiable precipitating event, a final episode of erythema developed around the eyes that lasted only 3 days. She has subsequently remained clear for 3 years of follow-up (Fig 1C).

Case 2 (49-Year-Old Woman—Seborrheic Dermatitis)

This patient developed a rash on the sides of her nose and upper cheeks that prompted her, 6 years before her initial consultation with us, to begin using low-potency topical corticosteroids (Fig 2A). In the 18 months before her consultation, IM and oral corticosteroids were repeatedly prescribed for persistent and worsening facial

rash. Patch testing was entirely negative. On corticosteroid withdrawal, her entire face developed redness and severe burning that extended down to her neck (Fig 2B). Eight episodes of flare occurred, each lasting 5 to 10 days. By the tenth month off corticosteroids, the flares stopped completely, and she has remained clear for 3 years.

Post-Peel (Laser) Erythema Syndrome

We recently reported 12 patients who developed persistent facial erythema after phenol peel or laser resurfacing for aging skin.⁶ Three patients had used topical corticosteroids before the procedure for atopic or seborrheic dermatitis, and one had used a superpotent cor-

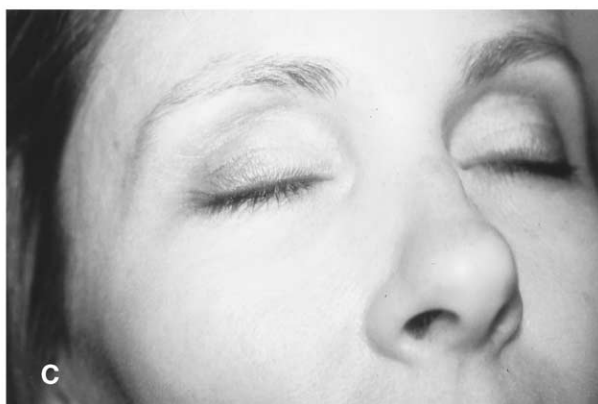
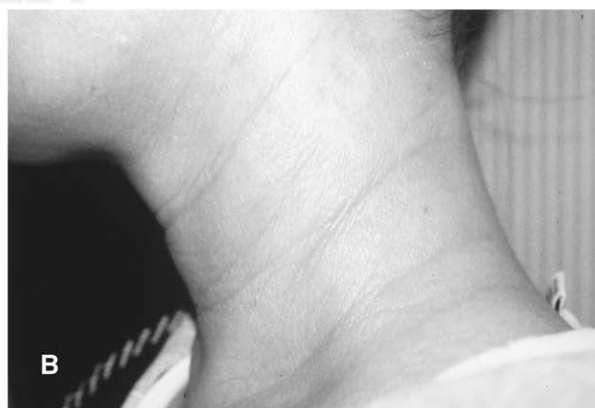
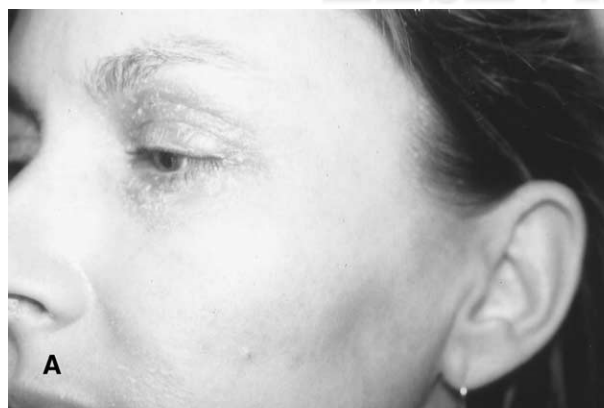
Figure 1. Case 1: three slides. A: 9 months of corticosteroid applications for eyelid dermatitis (slide 1). B: 10 days after corticosteroids stopped—flare on neck (slide 2). C: 24 months after cessation of corticosteroids, no flares for 18 months (slide 3).

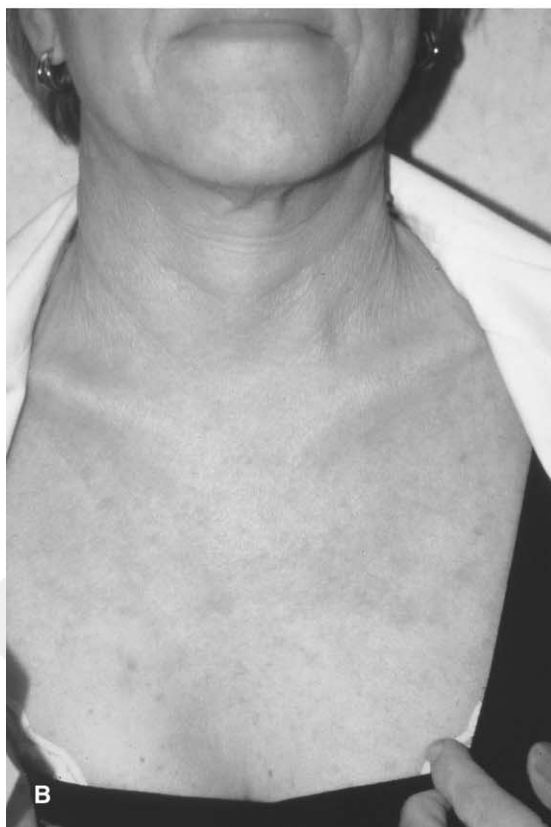
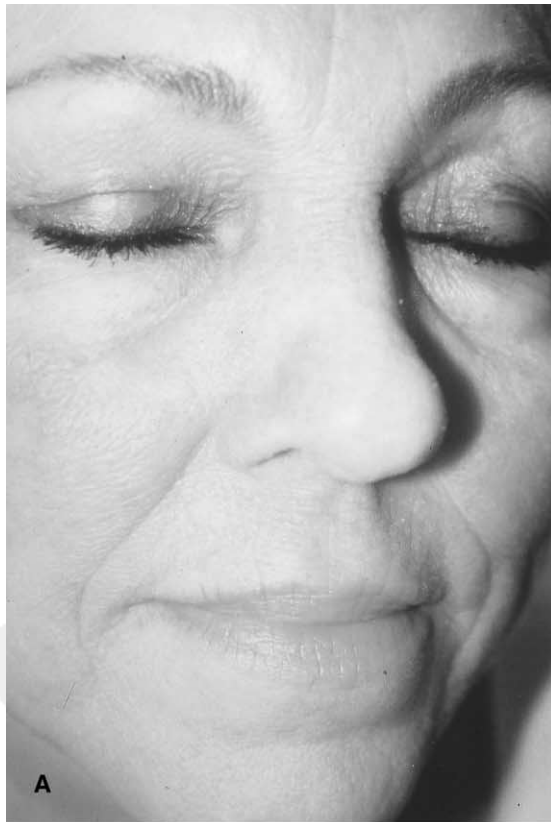
Figure 2. Case 2: two slides. A: 6 years of corticosteroid application to cheeks (slide 1). B: 1 month after cessation of corticosteroids—flare on face, neck, and chest (slide 2).

ticosteroid cream for 10 years for chronic eyelid dermatitis. This latter patient also applied the same preparation to the vaginal and anal areas for 8 years and developed a severe flare in these areas when corticosteroids were stopped.

Case 3 (74-year-old woman)

A right tenectomy had been performed 3 years before her initial consultation. At that time, she had also undergone a laser resurfacing procedure in the nasolabial area with a single pass of a CO₂ laser. After the procedure, she was told to apply medium-strength corticosteroid creams only to the nasolabial folds. With continued application of these creams, persistent erythema and burning developed that were treated with super-potent corticosteroid ointments and creams for 2 years. When first seen by us, she complained of continuous, fierce burning of the face; her cheeks were red and displayed a diffuse network of telangiectasia (Fig 3A). To sleep, she required two fans blowing cold air on her face throughout the night; she even talked of suicide. During the first year of corticosteroid withdrawal (Fig 3B), flares occurred every 2 to 3 weeks. Slowly, noninflamed areas of skin appeared in the preauricular and perioral areas. Then, during the eleventh month, with no obvious antecedent cause, she developed intense purple coloration of both cheeks (Fig 3C). This cleared after one week with no therapy other than ice compresses (Fig 3D). Flares of erythema stopped altogether after an additional year, but atrophy of the skin still remained.

Status Cosmeticus

Fisher⁷⁻⁹ described a group of woman patients unable to tolerate any cosmetics on the face because they caused a "disagreeable" sensation. They experienced mild erythema of the "butterfly area," often associated with mild eyelid edema and complained bitterly of burning and stinging. We have seen five patients with this condition, all of whom were atopics with mild facial erythema and burning that was disproportionate to the degree of redness. They had all applied weak corticosteroid preparations for months to years. Physical examination revealed slight atrophy, telangiectasia, and rare acneiform papules. With complete corticosteroid withdrawal, the atrophy eventually cleared, and stinging and burning vanished. Clearing usually took 8 to 12 months.

Case 4 (64-Year-Old Woman—Atopic)

Dermatitis of the right eyelid had developed 10 years earlier. She was treated by a number of physicians with an array of weak to moderate-strength corticosteroid creams and ointments. Despite treatment, a rash appeared on the other eyelid and on the rest of her face. The patient underwent extensive evaluation by dermatologists, allergists, and internists, including patch test-

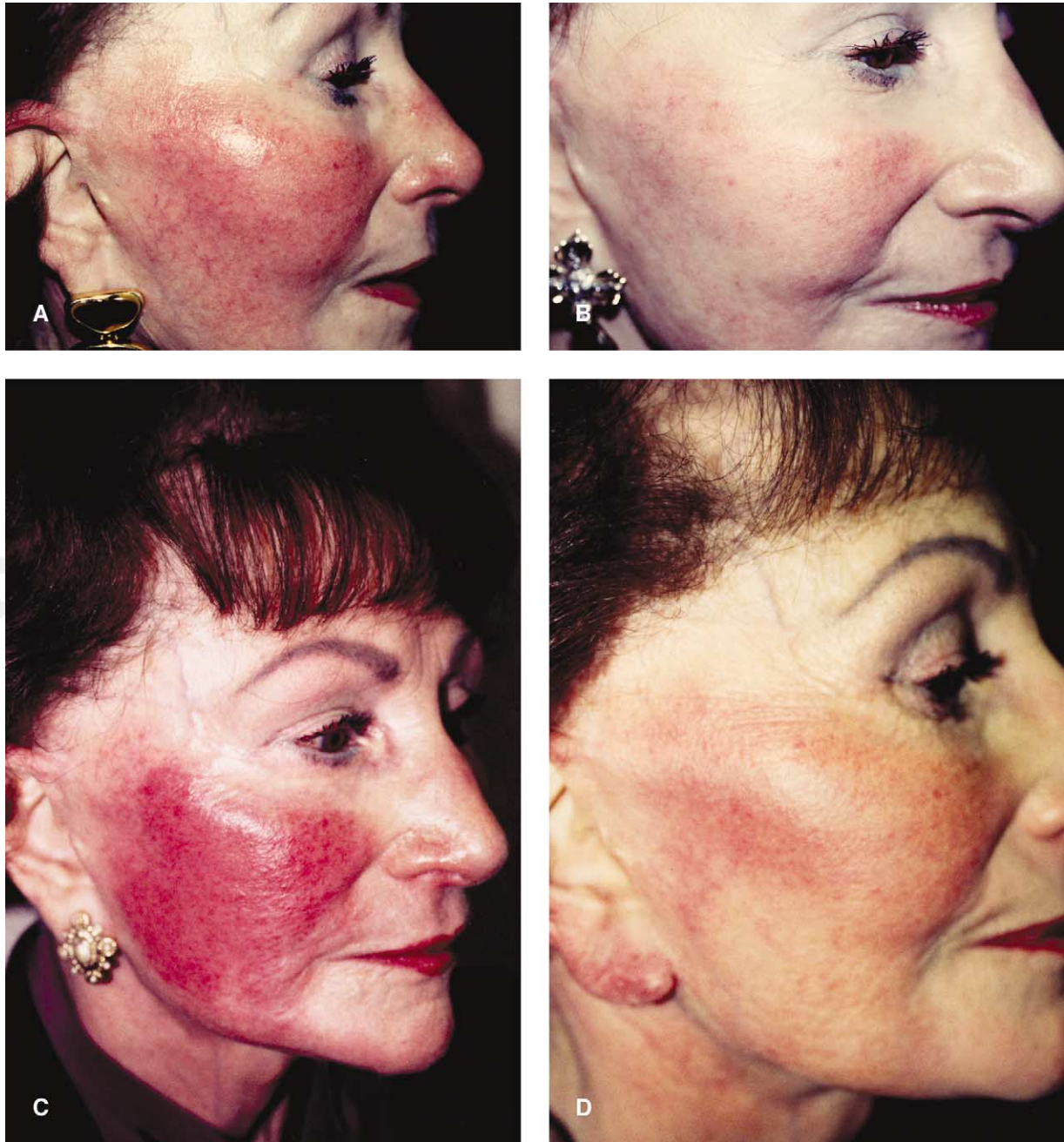

Figure 3. Case 3: four slides. A: 3 years of corticosteroid applications to nasolabial folds after laser treatment (slide 1). B: 3 months after corticosteroid cessation—marked erythema (slide 2). C: 8 months later—sudden onset of purple red coloration (slide 3). D: 1 week later—clearing and less burning (slide 4).

ing, scratch tests, and a systemic workup for immunologic and “paraneoplastic problems.” Therapy also included hypoallergenic soaps and lotions, but she continued using weak topical corticosteroids. When first seen by us, her face and eyelids exhibited minimal erythema, and the eyelid skin was atrophic with telangiectasia (Fig 4A). Patch testing revealed nonspecific positives to fragrance mix, merthiolate, potassium dichromate, lanolin and Balsam of Peru. When steroids were stopped, the redness on her cheeks flared but

eventually cleared after a few months. The burning and stinging sensations decreased slowly over a 10-month period. When the atrophy finally cleared, the burning sensation stopped as well (Fig 4b). She was then able to use all of her cosmetics again without any adverse reaction. She has had no rash or burning for the last 8 years.

Red Scrotum Syndrome

B.K. Fisher¹⁰⁻¹² coined the term “red scrotum syndrome” to describe a group of elderly white men who

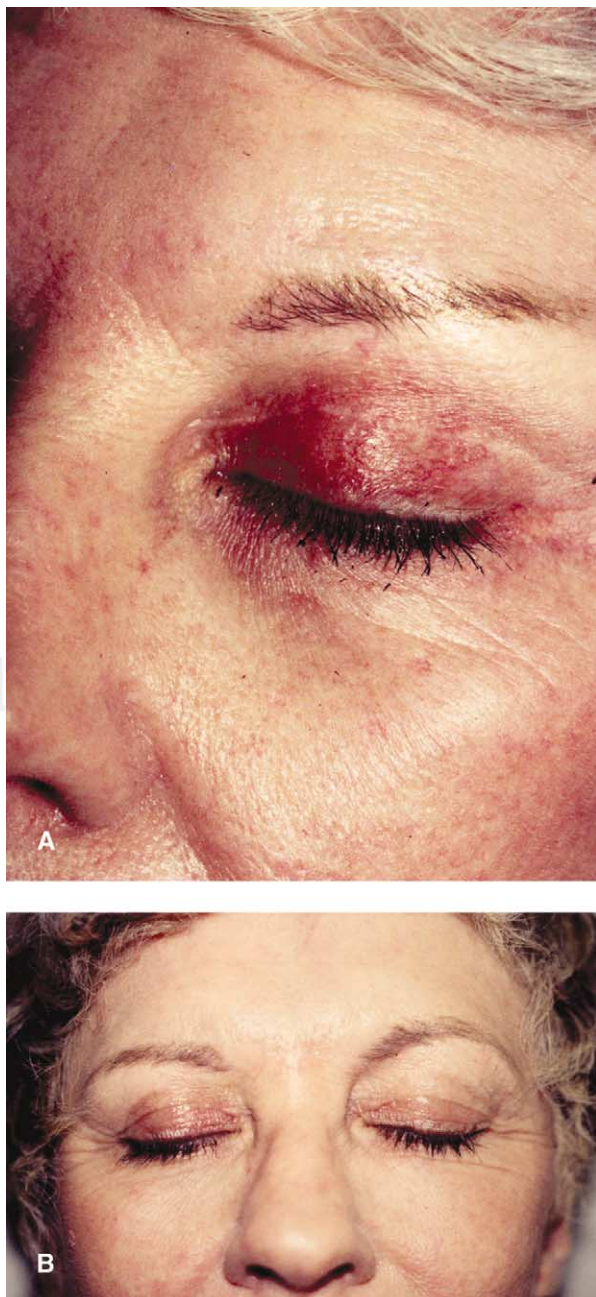

Figure 4. Case 4: two slides. A: Telangiectatic network with atrophy—burning skin sensation (slide 1). B: 11 months after corticosteroid cessation—no atrophy, no burning (slide 2).

had consulted him for an annoying scrotal rash. Erythema and telangiectasia were prominent on the anterior half of the scrotum, and despite the limited skin findings, the patients complained of constant, severe itching or burning. There was such hyperalgesia at times that the patients had to avoid sitting since the resulting pressure caused severe pain and burning. When Fisher presented these cases at dermatology meetings, many of the physicians in the audience reported that they had seen identical cases. Lynch¹³ sug-

gested that this idiopathic penile and scrotal pain associated with redness might be analogous to vulvodynia. Fisher's therapy was continual usage of corticosteroids and supportive psychologic care. English et al¹⁴ also described this problem, but offered no remedies.

We have treated 17 cases of chronic erythema and burning in the scrotal, inguinal, and penile areas. Our patients with "red scrotum syndrome" had used corticosteroids in the groin area for 5 to 15 years. They had initially been diagnosed with atopic dermatitis or irritant contact dermatitis. One patient used corticosteroids in the inguinal area for about 15 years for pruritus, in the anal area for 10 years also for pruritus, and on the face for 3 years to treat seborrheic dermatitis. When corticosteroids were stopped, the face cleared first, followed by the anal area 6 months later. A persistent erythema persisted on the scrotum for an additional year. Finally, only a small patch of erythema was evident on the penis for 3 months longer. The patient underwent acupuncture treatments at that time and believes that this brought on the final cure. He has remained clear for 1 year.

Case 5 (65-Year-Old Man—Atopic)

Six months before his initial consultation, after a long car trip, the patient noted a small irritated, red area on the scrotum. He applied topical hydrocortisone, triamcinolone, mupirocin, and ketoconazole and took oral prednisone, cephalexin, ciprofloxacin, itraconazole, amoxicillin, and clarithromycin at various times over the next 6 months. Corticosteroids were used daily. When he was first seen, an edematous, vesicular, erythematous rash on the penis and scrotum was evident (Fig 5A). This was associated with severe burning and pain. Patch testing was negative. After many episodes of flaring and clearing, he cleared totally after 7 months of steroid abstinence (Fig 5B). He has remained free of rash and symptoms for 4 years.

Vulvodynia

Vulvodynia¹⁵⁻¹⁸ has been classified into three subsets: vulvar vestibulitis (burning, irritation or rawness limited to the vulvar vestibule), essential vulvodynia (burning and rawness spreading from the vulvar vestibule to include the labia majora), and cyclic vulvodynia. At times, subtle erythema and scaling are present. Common therapies noted by a national vulvodynia association include intralesional corticosteroids with lidocaine, estradiol cream 0.1%, triamcinolone ointment 0.1%, and anticandidal therapy. Patients have also been placed on elimination diets, as yeast infections were suspect.

We have seen nine patients with this problem. All of them had been using topical corticosteroids, mostly of the superpotent variety for many years (range 3-18 years). Several patients with nonspecific vulvar irritation started with a triamcinolone/nystatin combination

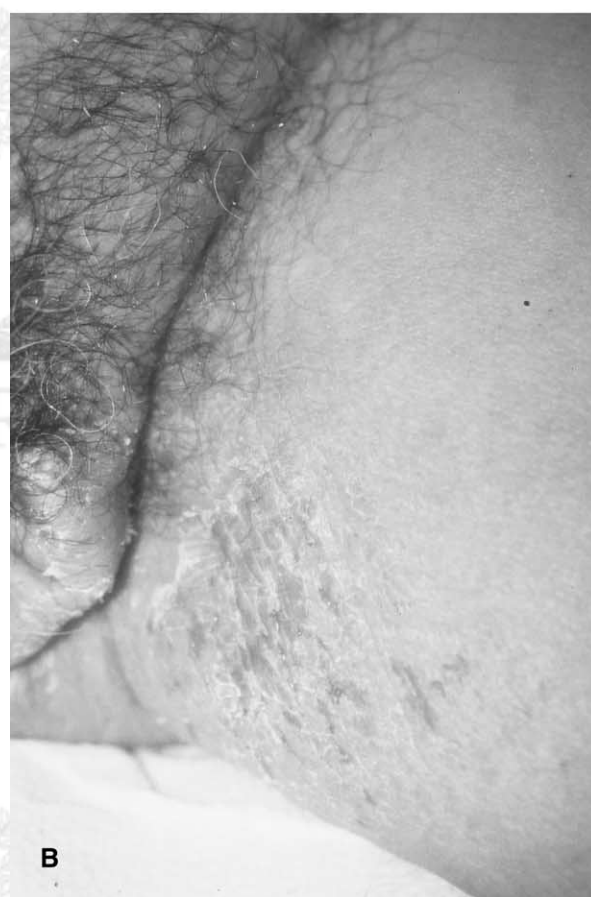
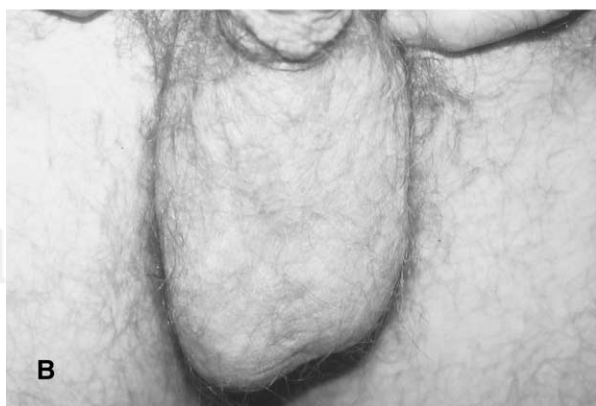
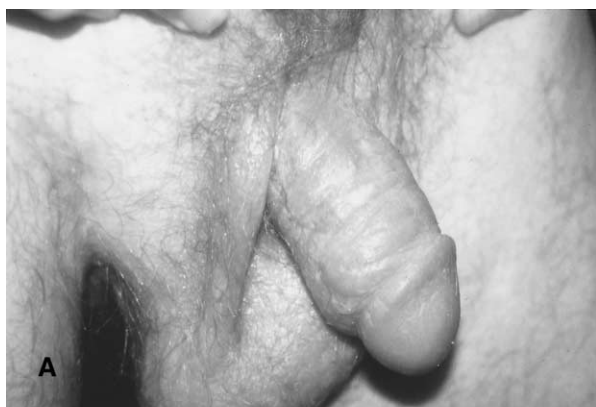Figure 5. Case 5: two slides. A: 8 months after corticosteroid applications began—erythema and edema (slide 1). B: 10 months after corticosteroid cessation—no flares for prior 3 mos (slide 2)

cream. Examination revealed a mild erythema in the vestibule or on the labia majora. The complaints of continual burning were usually out of proportion to the physical findings.

We believe that these patients are similar to steroid-treated cheilitis patients who also experience a severe burning sensation on the oral labial mucosa. Our 4 patients with cheilitis are included in the 201 patients with facial erythema. They all cleared in 8 to 12 months after stopping corticosteroids.

Case 6 (59-Year-Old Woman—Atopic)

This patient developed nonspecific vulvar and suprapubic itching and irritation 9 months before her initial consultation. Her medications included oral estrogen and progesterone hormone replacement therapy. During the 9-month period, she sought treatment from 7 physicians, mostly dermatologists (Fig 6A). She had used increasing amounts of topical corticosteroids, mostly of the superpotent variety. She had received multiple IM injections of triamcinolone and had also consulted an acupuncturist. An allergist treated her with “allergy shots.” Patch testing was negative. Upon cessation of corticosteroids, (estrogen and progesterone were also stopped) she continued to flare for 5 months.

Figure 6. Case 6: two slides. A: 9 months of corticosteroid application (slide 1). B: 4 months after steroid cessation—moderate edema, minimal erythema, and marked exfoliation (slide 2).

There was extremely severe burning in the vulvar and inguinal areas (Fig 6B), coupled with a spreading dermatitis on the legs, eyelids, and hands and below both breasts. She flared six times. After five months, no other exacerbations occurred, and she has remained clear for 3 years. Oral hormone replacement therapy was not reinstated.

Perianal Atrophoderma

Six men and women presented with persistent anal erythema and burning. They all had used topical corticosteroids for from 1 to 12 years, and 4 had been given systemic corticosteroids. Goldman and Kitzmiller¹⁹ noted that in their 8 patients, persistent usage of fluorinated corticosteroids had occurred for from 2 to 11 years.

All of their patients had pruritus and atrophy, and six of the eight demonstrated telangiectasia. They could not be weaned off corticosteroids. Four of our patients have stayed clear for at least 4 years—withdrawal taking approximately 6 months. The two women who failed treatment and resumed corticosteroids had each been using these topicals for at least 12 years each. After 6 and 10 months, respectively, they still experienced severe flares and could not function without the topical “remedy.”

Case 7 (55-Year-Old Woman)

This atopic woman suffered from pruritus ani for approximately 12 years. She had used, with increasing frequency, topical midstrength corticosteroids and antifungal creams. All patch tests were negative. When corticosteroids were stopped, six severe flares of burning and pruritus occurred over the next several months. An expanding area of erythema in the perianal region extended to the midbuttocks, and there were numerous small areas of oozing (Fig 7). On two occasions, a flare of dermatitis occurred under the right breast and on both eyelids. She noted irritation, dermatitis, and burning in the vaginal area. It became increasingly difficult for her to sit and function at work, and she required analgesics and narcotics for relief. Her flares continued for 8 months. During a hospitalization for cancer of the breast, she felt it necessary to resume topical corticosteroids to facilitate a less stormy postoperative recovery. After successful mastectomy and 4 months of corticosteroid application, she was unable to discontinue these creams because of severe discomfort.

Chronic Actinic Dermatitis-Like Eruption

We have treated nine patients presenting with facial erythema and lichenified areas on the face, forearms, and upper neck. All demonstrated the “headlight” sign as described previously. The rash appeared to be photodistributed but did not flare on sun exposure; nevertheless, the patients used sunscreen.²⁰⁻²² Most of the patients experienced burning and itching throughout the year, but symptoms often increased in warm weather, with exercise, or increased ambient heat. A few patients were worse during winter months. Patch testing gave variable, inconsistent, and irrelevant results.^{23,24} Photograph testing was not performed because of the extreme skin irritability noted during patch testing and because of the negative history of sun sen-

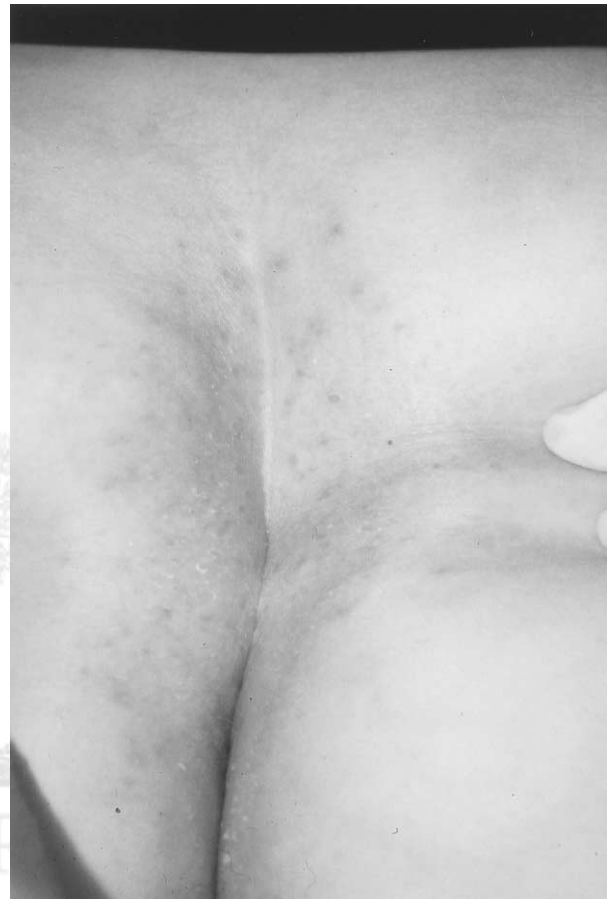


Figure 7. Case 7: one slide. Six months after corticosteroid cessation—oozing, vesicular rash.

sitivity. Six patients cleared after periods of from 9 to 16 months and remained clear for 1 to 6 years of follow-up. The other three patients resumed steroid usage. UVA/UVB therapy was given to all of the patients.²⁵⁻²⁸

Case 8 (74-Year-Old Woman—Atopic)

This patient had used topical corticosteroids on her arms for 25 years and on her face and neck for the past 8 years. When the rash became more widespread, she wore “body suits” at night over the steroids. She received IM corticosteroid injections on rare occasions and was instructed to avoid sun and to use sunscreen. When first seen by us, she had been using a low-potency corticosteroid on her face daily for the preceding 18 months. Patch testing revealed definite 2+ reactions to cocamidopropyl betaine and potassium dichromate and a severe 3+ reaction to nickel, which were not clinically relevant. Her face was bright red with a headlight sign, and there was severe burning of the neck, which appeared atrophic and telangiectatic (Fig 8A). When corticosteroids were stopped, the burning became so severe that she required analgesics and tranquilizers. Flares of facial erythema were associated with edema and dermatitis on her legs and arms. After

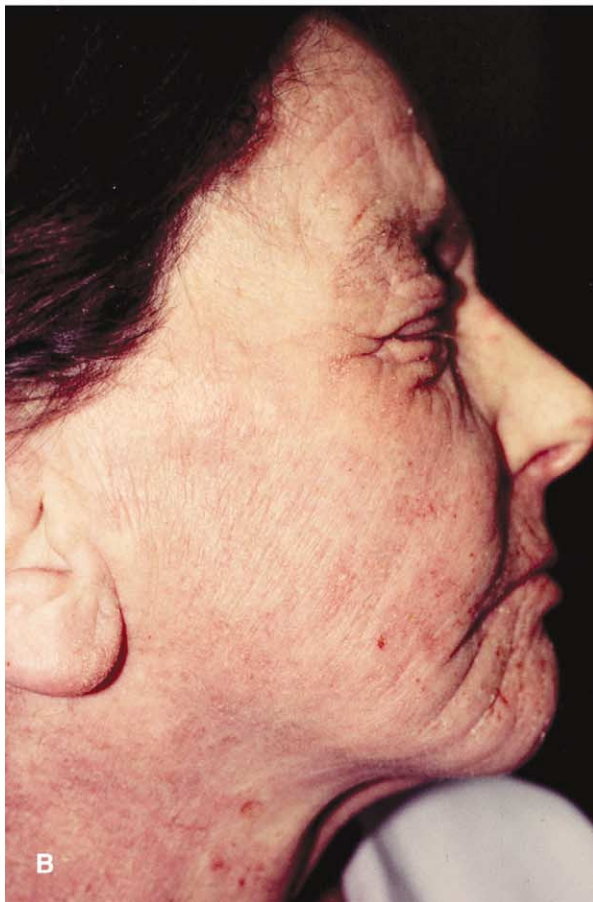
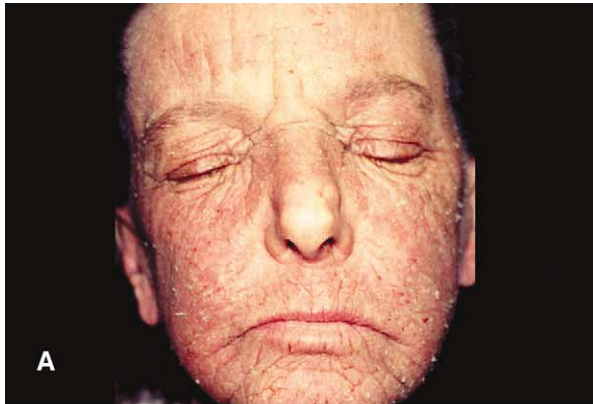
Figure 8. Case 8: two slides. A: 25 years of corticosteroid applications to face, neck and arms (slide 1). B: 11 months after corticosteroid cessation—white areas of face are becoming evident, burning sensation has stopped, skin on neck atrophic.

11 months, she was totally clear except for erythema on the cheeks (Fig 8B). Intermittent severe burning occurred on the neck, and atrophy was still present. At 12 months, she was 90% clear except for a few small areas of erythema and burning on the neck and face. She tolerated moderate sun exposure without difficulty and was treated with UVA/UVB phototherapy without any exacerbation.

Table 2. Chronic eczema—other body areas

Areas	Cases
Axilla	5
Chest and trunk	24
Neck	4
Scalp	2
Feet (dorsum)	1
Legs	4
Hands (palmar)	11
Arms	5

“Chronic Eczema”—Other Body Areas

Fifty-six additional patients had used corticosteroids chronically on miscellaneous body areas and experienced unusual patterns of flare on steroid withdrawal. In those patients who had treated multiple sites, all areas flared, the longest treated site taking the longest to clear. Localized vesiculation and oozing coupled with edema of the ankles and hands were common. Patches of nummular eczema sometimes appeared in distant areas where there previously had been no involvement.

Case 9 (75-Year-Old Woman—Atopic)

This patient, who had experienced only minor “winter itch” over the past 25 years, fractured her right forearm and was placed in a cast for 2 months. Upon removal of the cast, dermatitis was noted. She was treated with a variety of corticosteroid preparations including intralesional injections to multiple sites on the forearm, super-potent topical corticosteroids, IM injections of methylprednisolone, and three courses of oral prednisone 40 mg/day for 7 days.

On her initial consultation with us, she was noted to have marked atrophy of forearm skin. Skin biopsy showed spongiosis of the epidermis and numerous dilated vessels in the dermis. The distal forearm exhibited loss of subcutaneous tissue similar to cases of “disappearing digits.”^{29,30}

All patch tests were negative. When corticosteroids were stopped, a generalized papular dermatitis developed on the trunk, arms, and upper legs that cleared after 1 week. For the next 12 months, she experienced about 20 episodes of intense erythema, edema, vesiculation, and oozing on the forearm, mostly on the flexor aspect (Fig 9A). At 5 months, the skin on the dorsal aspect of the wrist and hand improved (Fig 9, B and C), and at 14 months, the flexor aspect cleared. She has since remained totally clear.

Case 10 (50-Year-Old Man)

This surgeon had a past history of childhood hay fever and eczema and had experienced chronic dermatitis on the dorsum of his hands for about 14 years. During this period, he had trained and then practiced at several

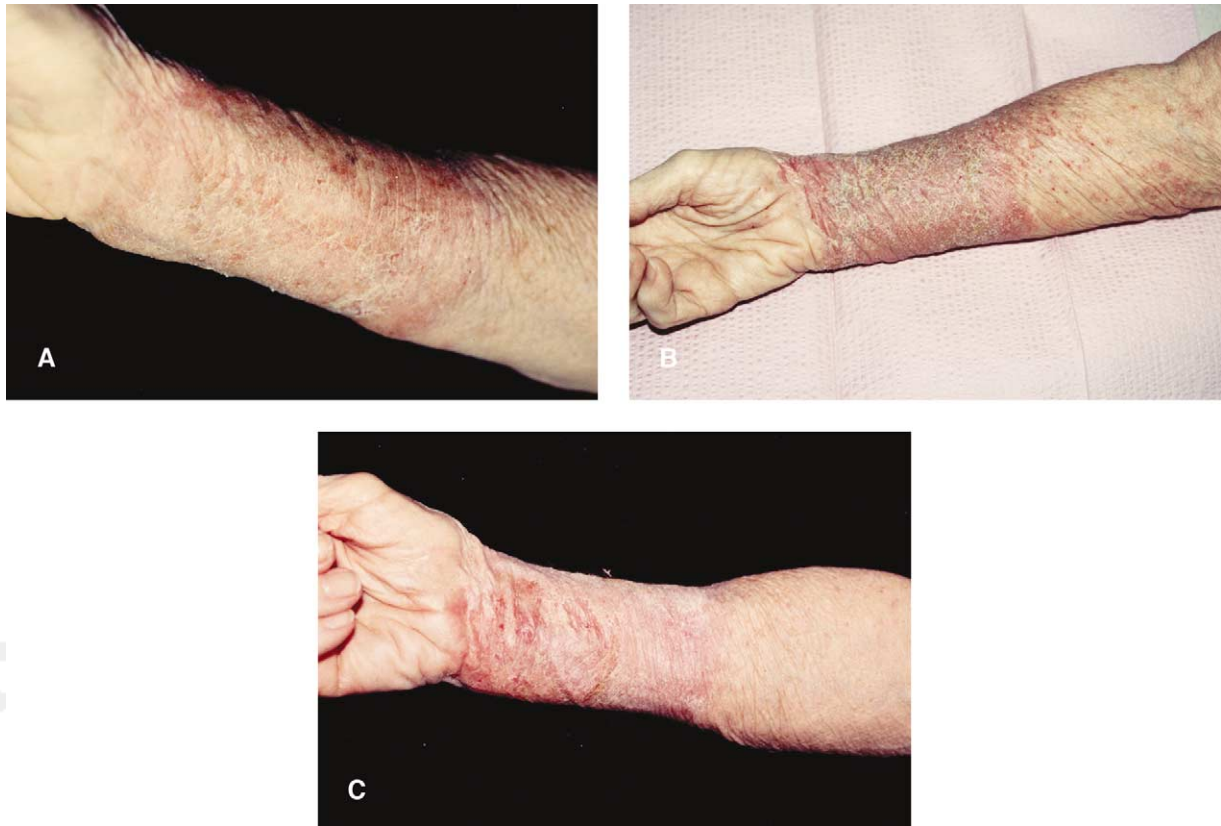


Figure 9. Case 9: three slides. A: 6 weeks after corticosteroid usage topically, systemically, and intralesionally (slide 1). B: 5 months after corticosteroid cessation—erythema, edema, and exfoliation. C: 9 months after corticosteroid cessation—atrophy of forearm (slide three).

institutions where he had been extensively evaluated. Previous patch testing showed positive reactions to formaldehyde and quaternium but negative reactions to rubber allergens and surgical gloves. No contact urticaria had ever been noted. The patient had been treated with daily superpotent topical corticosteroids for years and periodically with systemic corticosteroids.

Examination revealed atrophy, blanchable erythema, and telangiectasias on the dorsal aspect of the hands. The palmar aspects were completely spared. Patch test results included definite 2+ reactions to chloro-isothiazolinone, cinnamic aldehyde, cocamidopropyl betaine, and quaternium. Mild (1+) reactions to nickel sulfate and potassium dichromate also were seen. None of the patch test results were clinically relevant. His wife, who was a nurse, believed that the corticosteroids might be the cause of the eruption, and with her support these preparations were stopped. Although he experienced eight flares of erythema and burning over a 9-month period, he continued to work using latex and vinyl gloves. Interestingly, flares also occurred while he was on vacation. A mild 2-day flare occurred 8 months later on the dorsa of the hands, which cleared without therapy. He has remained clear for 3 years.

Discussion

This paper expands our original observations of facial “corticosteroid addiction” to include other areas of the body in addition to the face. A number of syndromes including “red face syndrome,” post-laser peel syndrome, status cosmeticus, “red scrotum syndrome,” vulvodynia, anal atrophoderma, chronic actinic dermatitis and “chronic eczema” in other body areas are illustrated. In all of these cases, long-term corticosteroids had been applied and resulted in a characteristic pattern of “corticosteroid addiction” which, in our opinion, is the etiologic factor in the ongoing dermatitis.

A number of early reports suggested that corticosteroids applied to the face have significant adverse effects; in fact, the term addiction was originally suggested 25 years ago.³¹⁻³³ Uehara et al reported on biopsies from 125 patients with this syndrome.³⁴ In their series, all of the patients demonstrated steroid rosacea, chronic eczema, a mixture of the two, or granulomas. Discontinuation of all topical steroids had been suggested, but since violent rebound inevitably occurred, oral corticosteroids were prescribed along with a so-called “safe” topical corticosteroid (negative on patch testing). Patient photographs in this series look exactly like our cases.

Tada et al described 87 atopic dermatitis patients who had severe refractory eruptions on the face, neck, and upper trunk.³⁵ They suggested that the etiology of dermatitis in Japanese patients might differ from that of western patients since topical nonsteroidal antiinflammatory agents are commonly used in Japan. Patch testing exhibited positives to shampoos, rinses, soaps, nonsteroidal antiinflammatory agents, cosmetics, and corticosteroids. Suggested causes for these cases of chronic dermatitis included: 1) long-term application of topical corticosteroids; 2) *Malassezia furfur* colonization; and 3) hypersensitivity to topical medicaments, cosmetics, and skin management products. In our opinion, all of the patients described likely suffered from corticosteroid addiction similar to our patients.

In recent years, corticosteroids have often been prescribed after resurfacing procedures to prevent hypertrophic scarring.⁶ Maloney et al used corticosteroids in all postlaser patients.³⁶ Erythema was seen for up to 1 year in some of their patients. Reviews of laser resurfacing describe prolonged erythema as a fairly common complication of the procedure and suggest that preoperative hydroquinone, tretinoin application, multiple laser passes, and postoperative dressings are the probable causes.³⁷⁻⁴⁰ The atopic individuals in our series had the most difficult and protracted courses after steroid cessation, whereas nonatopic individuals usually cleared within 2 to 3 months. Patients undergoing resurfacing procedures should be questioned about prior steroid usage on the face since they may be more likely to develop persistent erythema after the procedure.

When Fisher originally described "status cosmeticus" he considered that patients' symptoms resulted from occult, allergic contact or photocontact dermatitis or an urticarial etiology and that they had a tendency to seborrhea and rosacea. He speculated that occult chemicals in the cosmetics induced "stinging," but also considered that the "dermatologic nondisease," dysmorphobia, might be a factor since some of the patients were depressed and even suicidal. Most of these women had initially consulted ophthalmologists who had prescribed dexamethasone ophthalmic cream or ointment. Fisher recommended that milk compresses, followed by a light layer of 1% hydrocortisone ointment, be used in all cases. All of our patients with this condition cleared after complete withdrawal of steroids and were once again able to use all their cosmetics.

With regard to vulvodynia, McKay⁴¹ noted that her patients had a thin friable epithelium characteristic of atrophic vaginitis and exhibited diffuse genital erythema and burning. Many had treated their vulvar discomfort with betamethasone dipropionate 0.05% for months to years, and symptoms always worsened when steroid therapy was discontinued or tapered. Although Lewis⁴² reported contact sensitivity to an array

of chemicals in his series, our patients all showed negative patch tests.

All of our patients were either atopic or had experienced minor irritation or itching in the vulvar area. We believe that the vast majority continued to have symptoms solely because of their corticosteroid use. Our success in curing these individuals has been less dramatic than that achieved in other body areas. Nine of the 13 patients cleared and remained clear without further therapy but this took up to 18 months. The others could not tolerate cessation of their medication and resumed corticosteroid usage.

Corticosteroid Addiction Patterns

Approximately 90% of our patients had a history suggestive of atopy. The only significant variation from this pattern occurred in patients with facial dermatitis of whom approximately 20% had seborrheic dermatitis or "dry skin." Atopic characteristics included past history of eczema, asthma, hay fever, winter itch, soap or wool intolerance, hand eczema, family history of atopy, urticaria, intolerance to cosmetics, and history of nonspecific eczematous pruritus and rashes.

When dermatitis first developed in these patients, many of them self-prescribed over-the-counter 1% hydrocortisone cream or ointment. For those who sought medical consultation, many had been given moderate-strength corticosteroids initially, and in the past 5 years, superpotent corticosteroid preparations were commonly prescribed at the outset. When pruritus or rash persisted or when rash recurred, stronger corticosteroids or more frequent application was recommended. As skin complaints worsened, but now accompanied by burning, systemic corticosteroids, eg, IM triamcinolone or betamethasone, were administered from 2 to 8 times a year. Patients with red face syndrome, actinic dermatitis, and multisited atopic rashes commonly received this therapy. In addition, oral prednisone 20-80 mg/day was sometimes prescribed for varying periods of time.

In these initial phases of the addictive process, the corticosteroids were usually effective, and patients felt relief for weeks to months. As time passed, however, many patients required systemic corticosteroids at more frequent intervals, some every 6 to 10 weeks. Daily topical treatment only maintained tolerance of symptoms and mild diminution of the rash. Patients complained that corticosteroids "were not working anymore." It was at this time that the authors were consulted.

By this time, the initial limited areas of dermatitis had expanded significantly. The itch had mostly disappeared but had been replaced by severe burning that was only relieved by further topical corticosteroid application. The appearance of the dermatitis changed

and was now more of a hyperemia. Most topical non-steroidal preparations increased the burning, and this led patient and physician to believe that an occult allergen was the cause. In fact, in many cases the purpose of the initial referral was to identify that obscure allergen. This "addictive phase" took from 3 months to several years to develop.

Corticosteroid Withdrawal Patterns

After extensive workup failed to reveal any relevant contact allergens, systemic etiology, or infectious pathogens, all corticosteroids were stopped. Patients were required to discontinue all corticosteroids both topical and systemic. Approximately 5% of the patients were either unwilling to accept the diagnosis of corticosteroid addiction, or, because their initial flares on steroid cessation were so severe, were unable to comply. All of the others, although frustrated, adhered to the regimen of corticosteroid abstinence. Previous attempts to taper systemic and topical corticosteroid in these patients had resulted in severe rebound; a great deal of support and "hand-holding" were necessary.

The pattern of corticosteroid withdrawal was usually quite characteristic. Seven to 10 days after corticosteroids were stopped, an initial flare of erythema occurred at the site of the original dermatitis, accompanied by local spread and marked burning. This flare lasted anywhere from 7 to 14 days and culminated with exfoliation. Patients who had received systemic corticosteroids over a long period of time developed local edema and a serous exudate that cleared with drying and crust formation. Although bacterial cultures were negative, oral antibiotics were sometimes prescribed empirically and appeared to accelerate the time to clearing in some patients.

Dermatitis localized to the eyelids, face, scrotum, or perianal area often continued to burn and cause difficulty sleeping. Atrophy and telangiectasia were common in intertriginous areas. After a short-lived quiescent phase, a second flare usually occurred within 1 to 3 weeks. This pattern of flare and quiescence repeated itself but each time with flares of shorter duration and more prolonged quiescent periods. Edema, burning, and erythema decreased with each episode of flare.

The length of the time over which corticosteroids had been given usually determined the duration of the withdrawal phase. For facial rash, withdrawal periods ranged from 2 months to 2½ years. Table 1 describes the patterns of rash and the typical time framework from withdrawal to cure.

The different modes of corticosteroid delivery (topical, IM, intralesional, intranasal, conjunctival, oral, and occlusive) resulted in an assortment of clinical patterns. Patients often employed more than one delivery system when multiple body sites were affected. There were no

systemic adverse effects of steroid withdrawal, and other than occasional eosinophilia, no serious hematologic or blood chemistry abnormalities were noted.^{43,44} In three patients, inguinal striae persisted for more than 5 years but axillary striae were not seen.⁴⁵ In five patients, a final short-lived flare occurred about 3 to 5 months after previous flares had ceased. No precipitating event could be discerned for this peculiar phenomenon.

In addition to discontinuation of all corticosteroids, we instituted a therapeutic regimen of emollients, antihistamines, baths, Burow's solution, and ice compresses. As flares became progressively less severe, UVA and UVB treatments, one to three times a week, were begun in some patients. In five cases, PUVA was instituted when the initial atopic dermatitis had been very widespread. Two patients had tried topical tacrolimus⁴⁶ but had stopped because of increased irritation. Two of the patients with chronic actinic dermatitis were given a 2- to 3-month course of oral cyclosporin, 1 to 3 mg/kg/day, which appeared not to alter the course of the withdrawal phase. In no other instance were anti-mitotics, immunosuppressives, or immunomodulators utilized.^{47,48}

Patch Testing and "Allergy" to Corticosteroids

In previous reports, many of these syndromes have been attributed to contact allergy and even to steroid allergy. Approximately 90% of our patients were patch tested to an expanded list of allergens that, in addition to the standard tray, included several corticosteroid antigens, sunscreens, preservatives, and fragrances. Interpretation of patch test results was complicated because many of the patients were atopic.^{49,50} These patients often manifest irritant reactions and not uncommonly, develop the "angry back syndrome" that can confound patch test reading. We were unable to identify any relevant allergens in our patients. Two patients exhibited mildly positive patch tests to corticosteroid preparations, but both were negative on repeat patch testing and "usage tests."

There have recently been a number of case reports and reviews⁵¹⁻⁵⁴ suggesting the importance of corticosteroid allergy in patients with different patterns of dermatitis. The majority of patients in these reports were clinically similar to ours patients and many were atopic.^{53,55-58} Patients exhibiting "allergy" to one class of corticosteroids are said to tolerate other corticosteroid preparations.⁵⁹⁻⁶¹ Distant flares occurring in patients treated with systemic steroids are usually attributed to "systemic allergic reactions"⁶²⁻⁶⁵ These reports sometimes mention additional positive reactions to nonsteroidal chemicals, but the significance of these findings are rarely discussed. In our opinion, many so-called "positive" steroid patch tests likely represent irritant or vascular reactions, not true allergic reactions.

Although it is alleged that 2% to 8% of the population is allergic to tixocortol, the standard corticosteroid patch test allergen, our results in over 1000 patients do not bear this out.

Sholz questioned the validity of the concept of corticosteroid allergy; he wondered: 1) whether positive patch test results might represent an autoimmune phenomenon since hydrocortisone is normally produced in the body; and 2) how could these patients tolerate systemic corticosteroid therapy when they showed contact allergy to these preparations.⁶⁷⁻⁷³ Discussions of "corticosteroid allergy" have examined the significance of differing chemical structures, cross-reactivity among corticosteroid compounds, relevance of tixocortol allergy, and possible cross-reaction with progestational and estrogen compounds. The latter may be meaningful in the vulvodynia patients receiving these compounds in addition to the corticosteroids.^{84,85}

Reports of "allergy" to inhaled corticosteroids⁶⁷⁻⁷³ used for the treatment of sinusitis and bronchitis also have appeared. Could the same rebound phenomenon and flaring be occurring in the nasal, sinus, and bronchial mucosa?

Kligman (personal communication, 1999) suggested that the occurrence of contact dermatitis to corticosteroids has been grossly exaggerated and that reported prevalence rates of up to 8% of the population are unlikely. He notes that atopics frequently express the "angry back syndrome" and often have unusual, non-reproducible patch test reactions. In fact, he has encountered erythematous reactions to petrolatum in 20% of normal people. In his experience, duplicate patches may have a concordance of only 50%. In addition, the patch test reaction for a given antigen may vary from 0 to 3+ over the course of a year. Thus, patch test results can be misleading in the absence of corroborating evidence. With regard to delayed systemic allergic reactions to corticosteroids, Whitmore, in analyzing 24 cases from the literature, considered it a rare phenomenon with wide variability.⁶⁵ Twenty-five percent of cases reported were not supported by patch test data.

Cases of so-called "disappearing digits" have been reported after long-term application of corticosteroids to finger eczema. One report notes that Glaxo files demonstrate clobetasol to be 1800 times stronger than hydrocortisone. This is highly relevant since clobetasol has been prescribed commonly over the past 10 years.^{9,10}

In addition to the overuse of prescribed topical corticosteroids and over-the-counter hydrocortisone preparations, many sources of illicit and hidden corticosteroids exist. A recent newspaper exposé cited advertisements for depigmenting "cosmetics" that actually contained clobetasol or other superpotent corticosteroids.⁷⁴ Some supposedly "natural and nonmedicinal" Chinese "herbal creams" used for childhood

eczema have been shown to contain highly potent betamethasone 0.05%.⁷⁵ Finally, an influential cosmetic company began distributing an "exceptionally soothing cream" for "upset skin" that was promoted to calm the influence and irritation from pollutants, weather, and stress. Although not advertised as a corticosteroid, it contains hydrocortisone acetate 1%.

Mechanisms

The mechanism by which steroid addiction occurs is not known. Possible mechanisms might involve an effect on the "skin immune system," a direct effect on blood vessels in the skin or effects on the pituitary-adrenal axis. The continual use of topical or systemic corticosteroids initiates a preatrophic phase leading to an atrophic state with tachyphylaxis.⁷⁶⁻⁷⁸ With the ensuing atrophy, a burning sensation becomes prominent; continued steroid usage brings on vasoconstriction and soothes the burning.⁷⁹⁻⁸¹ The cycle of repeated vasoconstriction/vasodilation, sometimes called the "neon sign" or "trampoline effect," continues until the vasculature becomes fully dilated as a physiologic response. The mechanism by which this occurs is thought to reflect the suppressive effect of corticosteroids on nitric oxide (NO) in the endothelium. Release of accumulated endothelial NO stores eventuates in "hyperdilation" of vessels beyond their original diameters.^{86,87} Finally, local steroid spread causes extension of erythema, atrophy, and rash beyond the original site and even at distant sites.^{82,83}

References

1. Rapaport MJ, Rapaport V. Eyelid dermatitis to red face syndrome to cure: clinical experience in 100 cases. *J Am Acad Dermatol* 1999;41:435-42.
2. Engasser PG, Hogan DJ, Stewart LA, Zug KA. Evaluation and management of the "red face." *Am J Contact Dermatitis* 1999;10:236-9.
3. Garner LA, Cruz PD, Jr. Worsening of a recurrent facial eruption despite treatment. *Am J Contact Dermatitis* 1999; 10:81-2.
4. Katz AS, Sherertz EF. Facial dermatitis: patch test results and final diagnosis. *Am J Contact Dermatitis* 1999;10: 153-6.
5. Bender B, Prestia AE, Lynfield YL. The headlight sign in neurodermatitis. *Cutis* 1969;5:1406-8.
6. Rapaport MJ, Rapaport V. Prolonged erythema after facial laser resurfacing or phenol peel secondary to corticosteroid addiction. *Dermatol Surg* 1999;25:781-5.
7. Fisher AA. Part I. "Status cosmeticus:" a cosmetic intolerance syndrome. *Cutis* 1990;46:109-10.
8. Fisher AA. Part II. The management of eyelid dermatitis in patients with "status cosmeticus:" the cosmetic intolerance syndrome. *Cutis* 1990;46:199-201.
9. Fisher AA. Cosmetic intolerance syndrome. In: *Contact Dermatitis*, 4th edition, Rietschel R, Fowler J (Eds.). Philadelphia: Williams & Wilkins 1995:316-8.

10. Fisher BK. The red scrotum syndrome. *Cutis* 1997;60:139-41.
11. Rapaport M. Letters to the editor. *Cutis* 1998;61:128B.
12. Fisher BK. Letters to the Editor. *Cutis* 1998;61:128B.
13. Lynch PJ, Edwards L (Eds.). Penile and scrotal pain. In: *Genital Dermatology*. New York: Churchill Livingstone, 1994: 247-8.
14. English JC, Laws RA, Keough GC, et al. Dermatoses of the glans penis and prepuce. *J Am Acad Dermatol* 1997;37:1-24.
15. Mroczkowski TF. Vulvodynia—a dermatovenereologist's perspective. *Int J Dermatol* 1998;37:567-9.
16. Goetsch MF. Vulvar vestibulitis: prevalence and history features in a general gynecological practice population. *Am J Obstet Gynecol* 1991;164:1609-16.
17. Baggish MS, Miklos JR. Vulvar pain syndrome: a review. *Obstet Gynecol Surg* 1995;50:618-27.
18. Lynch PJ. Vulvodynia: a syndrome of unexplained vulvar pain, psychologic disability and sexual dysfunction. The 1985 ISSVD Presidential Address. *J Reprod Med* 1986;31:773.
19. Goldman L, Kitzmiller KW. Perianal atrophoderma from topical corticosteroids. *Arch Dermatol* 1973;107:611-2.
20. Lim HW, Buchness MR, Ashinoff R, Soter NA. Chronic actinic dermatitis. *Arch Dermatol* 1990;126:317-23.
21. Roelandts R. Chronic actinic dermatitis. *J Am Acad Dermatol* 1993;28:240-9.
22. Norris P, Hawk J. Chronic actinic dermatitis. A unifying concept. Editorials. *Arch Dermatol* 1990;126:376-8.
23. Lim HW, Morison WL, Kamide R, et al. Chronic actinic dermatitis. *Arch Dermatol* 1994;130:1284-9.
24. Lim HW, Cohen D, Soter NA. Chronic actinic dermatitis: results of patch and photopatch tests with compositae, fragrances, and pesticides. *J Am Acad Dermatol* 1998;38:108-11.
25. du P. Menage H, Ross JS, Norris PG, et al. Contact and photocontact sensitization in chronic actinic dermatitis: sesquiterpene lactone mix is an important allergen. *Br J Dermatol* 1995;132:543-7.
26. Frain-Bell W, Johnson BE. Contact allergic sensitivity to plants and the photosensitivity dermatitis and actinic reticuloid syndrome. *Br J Dermatol* 1979;101:503-12.
27. Frain-Bell W, Scatchard M. The association of photosensitivity and atopy in the child. *Br J Dermatol* 1971;85:105-110.
28. Addo HA, Ferguson J, Johnson BE, Frain-Bell W. The relationship between exposure to fragrance materials and persistent light reaction in the photosensitivity dermatitis with actinic reticuloid syndrome. *Br J Dermatol* 1982;107:261-74.
29. Deffer TA, Goette DK. Distal phalangeal atrophy secondary to topical steroid therapy. *Arch Dermatol* 1987;123:571-2.
30. Wolf R, Tur E, Brenner S. Corticosteroid-induced disappearing digit. *J Am Acad Dermatol* 1990;23:755-6.
31. Kligman A, Leyden JJ. Adverse effects of fluorinated steroids applied to the face. *JAMA* 1974;229:60-2.
32. Leyden JJ, Thew M, Kligman AM. Steroid rosacea. *Arch Dermatol* 1974;110:619-62.
33. Kligman AM, Frosch PJ. Steroid addiction. *Int J Dermatol* 1979;18:23-31.
34. Uehara M, Mitsuyoshi O, Sugiura H. Diagnosis and management of the red face syndrome. *Dermatol Ther* 1996;1:19-23.
35. Tada J, Yamasaki H, Toi Y, et al. Is the face and neck pattern of atopic dermatitis in Japan a special variant? *Am J Contact Dermatitis* 1999;10:7-11.
36. Maloney BP, Millman B, Monheit G, McCullough EG. The etiology of prolonged erythema after chemical peel. *Dermatol Surg* 1998;24:337-41.
37. Rendon-Pellerano MI, Lentini J, Eaglstein WE, Kirsner RS, Hanft K, Pardo RJ. Laser resurfacing: usual and unusual complications. *Dermatol Surg* 1999;25:360-7.
38. Ratner D, Tse Y, Marchell N, et al. Cutaneous laser resurfacing. *J Am Acad Dermatol* 1999;41:365-89.
39. Ruiz-Esparza J, Barba-Gomez JM, Gomez-De La Torre OL, David L. Erythema after laser skin resurfacing. *Dermatol Surg* 1998;24:31-4.
40. Nanni CA, Alster TS. Complications of cutaneous laser surgery. *Dermatol Surg* 1998;24:209-19.
41. McKay M. Vulvodynia. *Arch Dermatol* 1989;125:256-262.
42. Lewis FM, Shah M, Gawkrödger DJ. Contact sensitivity in pruritus vulvae: patch test results and clinical outcome. *Am J Contact Dermatitis* 1997:137-40.
43. Gilbertson EO, Spellman MC, Piacquadio DJ, Mulford MI. Super potent topical corticosteroids use associated with adrenal suppression: clinical considerations. *J Am Acad Dermatol* 1998;38:318-21.
44. Yawalkar N, Hari Y, Helbling A et al. Elevated serum levels of interleukins 5, 6 and 10 in a patient with drug-induced exanthem caused by systemic corticosteroids. *J Am Acad Dermatol* 1998;39:790-3.
45. Sorenson GW, Odom RB. Axillary and inguinal striae induced by systemic absorption of a topical corticosteroid. *Cutis* 1976;17:355-6.
46. Ruzicka T, Assmann T, Homey B. Tacrolimus. The Drug for the Turn of the Millennium? *Arch Dermatol* 1999;135:574-80.
47. Jolles S, Hughes J, Rustin M. Intracellular interleukin-4 profiles during high-dose intravenous immunoglobulin treatment of therapy-resistant atopic dermatitis. *J Am Acad Dermatol* 1999;40:121-3.
48. Noosari H, Anhalt G, Morrison W. Mycophenolate in Psoralen-UV-A desensitization therapy for chronic actinic dermatitis. *Arch Dermatol* 1999;135:1128-9.
49. Albert MR, Chang YC, Gonzalez E. Concomitant positive reactions to allergens in a patch testing standard series from 1988-1997. *Am J Contact Dermatitis* 1999;10:219-23.
50. Williams H. Diagnostic criteria for atopic dermatitis. Where do we go from here? *Arch Dermatol* 1999;135:583-6.
51. Dooms-Goossens A. Corticosteroid contact allergy: a challenge to patch testing. *Am J Contact Dermatitis* 1993;4:120-2.
52. Jagodzinski LJ, Taylor JS, Oriba H. Allergic contact dermatitis from topical corticosteroid preparations. *Am J Contact Dermatitis* 1995;6:67-74.
53. Schoenmakers A, Vermorken A, Degreef H, Dooms-Goossens A. Corticosteroid or steroid allergy? *Contact Dermatitis* 1992;26:159-62.

54. Thomson KF, Wilkinson SM, Powell S, Beck MH. The prevalence of corticosteroid allergy in two U. K. centres: prescribing implications. *Br J Dermatol* 1999;141:863–6.
55. Wilkinson SM, English JSC. Hydrocortisone sensitivity: clinical features of fifty-nine cases. *J Am Acad Dermatol* 1992;27:683–7.
56. Atkinson SM, Beck MH. Is tixocortol pivalate a photoallergen? *Contact Dermatitis* 1995;33:55–6.
57. Doms-Goossens A. What's new in contact dermatitis. *Am J Contact Dermatitis* 1993;4:120–2.
58. Reitamo S, Lauerma S, Stubb S, et al. Delayed hypersensitivity to topical corticosteroids. *J Am Acad Dermatol* 1986;14:582–98.
59. Guin JD. Contact sensitivity to topical corticosteroids. *J Am Acad Dermatol* 1884;10:773–82.
60. Wilkinson SM, English JSC. Patch tests are poor detectors of corticosteroid allergy. *Contact Dermatitis* 1992;26:67–8.
61. Lauerma AI, Kanerva L. Contact allergy to corticosteroids. *Int J Dermatol* 1996;35:92–4.
62. Murata Y, Kumano K, Ueda T, et al. Systemic contact dermatitis caused by systemic corticosteroid use. *Arch Dermatol* 1997;133:1053–4.
63. English JSC, Ford G, Beck MH, et al. Allergic contact dermatitis from topical and systemic steroids. *Contact Dermatitis* 1990;23:196–8.
64. Lauerma AI, Reitamo S. Contact allergy to corticosteroids. *J Am Acad Dermatol* 1993;28:618–22.
65. Whitmore E. Delayed systemic allergic reactions to corticosteroids. *Contact Dermatitis* 1995;32:193–8.
66. Sholz JR. Corticosteroid contact allergic dermatitis—some questions. *Am J Contact Dermatitis* 1990;1:14–142.
67. Doms-Goossens A. Allergy to inhaled corticosteroids: a review. *Am J Contact Dermatitis* 1995;6:1–3.
68. Bircher AJ. Short induction phase of contact allergy to tixocortol pivalate in a nasal spray. *Contact Dermatitis* 1990;227:237–8.
69. Clark RJ. Exacerbation of asthma after nebulised beclomethasone dipropionate. *Lancet* 1986;574–5.
70. McGivern DV, MacFarlane JT. Severe bronchoconstriction after inhalation of budesonide. *Br Med J* 1984;288:447–9.
71. Pierard GE, Pierard-Franchimont C, Mosbah T, et al. Adverse effects of topical corticosteroids. *Acta Derm Venereol (Stockh)* 1989;69:26–30.
72. Callens A, Vaillant L, Machet C, et al. Contact stomatitis from tixocortol pivalate. *Contact Dermatitis* 1993;29:161.
73. Meding B, Dahlberg E. Contact allergy to budesonide in a nasal spray. *Contact Dermatitis* 1986;14:253–4.
74. Willan, C. Steroid creams sell briskly (and illicitly) as cosmetics. *Wall Street J*, August 1999; Health: B1.
75. Keane FM. Analysis of Chinese herbal creams prescribed for dermatologic conditions. *Br J Med* 1999;318:563–4.
76. Katz IH, Prawer SE, Mooney JJ, et al. Preatrophy: covert sign of thinned skin. *J Am Acad Dermatol* 1989;20:731–5.
77. du Vivier A. Tachyphylaxis to topically applied steroids. *Arch Dermatol* 1976;76(112):1245–8.
78. Dykes PJ, Marks R. An appraisal of the methods used in the assessment of atrophy from topical steroids. *Br J Dermatol* 1979;101:599–606.
79. Lavker RM, Schechter NM, Lazarus GS. Effects of topical corticosteroids on human dermis. *Br J Dermatol* 1986;115:101–7.
80. Shah VP, Peck CC, Skelly JP. Vasoconstriction-skin blanching-assay for glucocorticoids—a Critique. *Arch Dermatol* 1989;125:1558–61.
81. Marks R, Sawyer M. Glucocorticoid-induced vasoconstriction in human skin. *Arch Dermatol* 1986;122:881–3.
82. Hogan DJ, Rooney ME. Facial telangiectasias associated with long-term application of a topical corticosteroid to the scalp. *J Am Acad Dermatol* 1089;20:1129–30.
83. Hessel A, Zyniewicz K. Facial blanching caused by superpotent corticosteroids. *Cutis* 1991;48:395–6.
84. Lepoittevin JP, Drieghe J, Doms-Goossens A. Studies in patients with corticosteroid contact allergy. Understanding cross-reactivity among different steroids. *Arch Dermatol* 1995;131:31–7.
85. Kalish RS. Studies in patients with corticosteroid contact allergy: a flawed analysis of structure-function relationships. *Arch Dermatol* 1995;131:851–2.
86. Ganong WF. Cardiovascular regulatory mechanisms. In: Holmes SA, editor. *Review of medical physiology*. Norwalk (CT): Appleton & Lange, 1991:50–1.
87. Berne RM, Levy MN. The microcirculation and lymphatics. In: Underdown E, editor. *Physiology*, 4th ed. St. Louis: Mosby, 1998:429–32.